

Deep learning algorithm to detect coronary artery tortuosity in coronary angiography

Miriam Cobo Cano¹ (FPU21/04458)

cobocano@ifca.unican.es

Francisco Pérez-Rojas^{2,4}, Constanza Gutiérrez-Rodríguez², Ignacio Heredia¹, Patricio Maragaño-Lizama³, Francisca Yung-Manriquez², José A. Vega^{2,4}, Lara Lloret Iglesias¹
¹Institute of Physics of Cantabria (CSIC-UC); ²Autonomous University of Chile; ³Talca Regional Hospital; ⁴University of Oviedo

CHALLENGE

- Coronary artery tortuosity (CAT) is often an undetected condition in patients undergoing coronary angiography (CAG).
- Detailed knowledge of the morphology of coronary arteries is essential for planning any interventional treatment.
- Objective:** develop a deep learning (DL) algorithm capable of automatically detecting CAT in CAG. Assess the performance of the DL algorithm against independent experts' radiological visual examination (RVE).
- Result:** DL had comparable sensitivity and specificity with RVE for detecting CAT for a conservative threshold of 0.5. Promising applications in the field of cardiology and medical imaging.

METHODS

The experimental dataset collected for this retrospective clinical study consisted of 658 CAG images, corresponding to 401 different patients.

Projection	# patients with coronary artery tortuosity	# patients without coronary artery tortuosity
Left or Spider	182	217
Right or 45°/0°	52	207

Table 1. Available images for each angiographic projection.

5-fold cross-validation models comprised the DL algorithm. Images were randomly selected (450 for training, 46 validation, 48 testing).

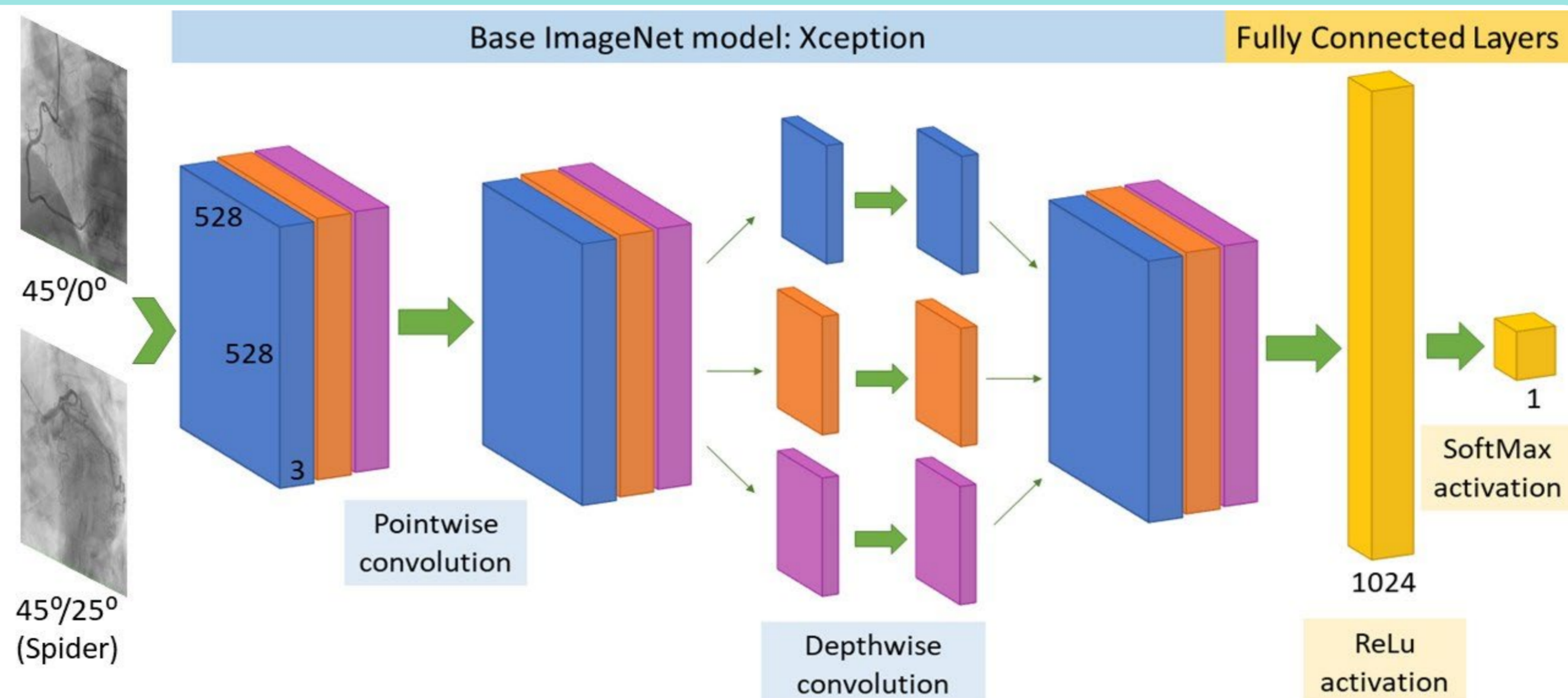


Figure 1. Proposed convolutional neural network architecture for CAT detection.

RESULTS & DISCUSSION

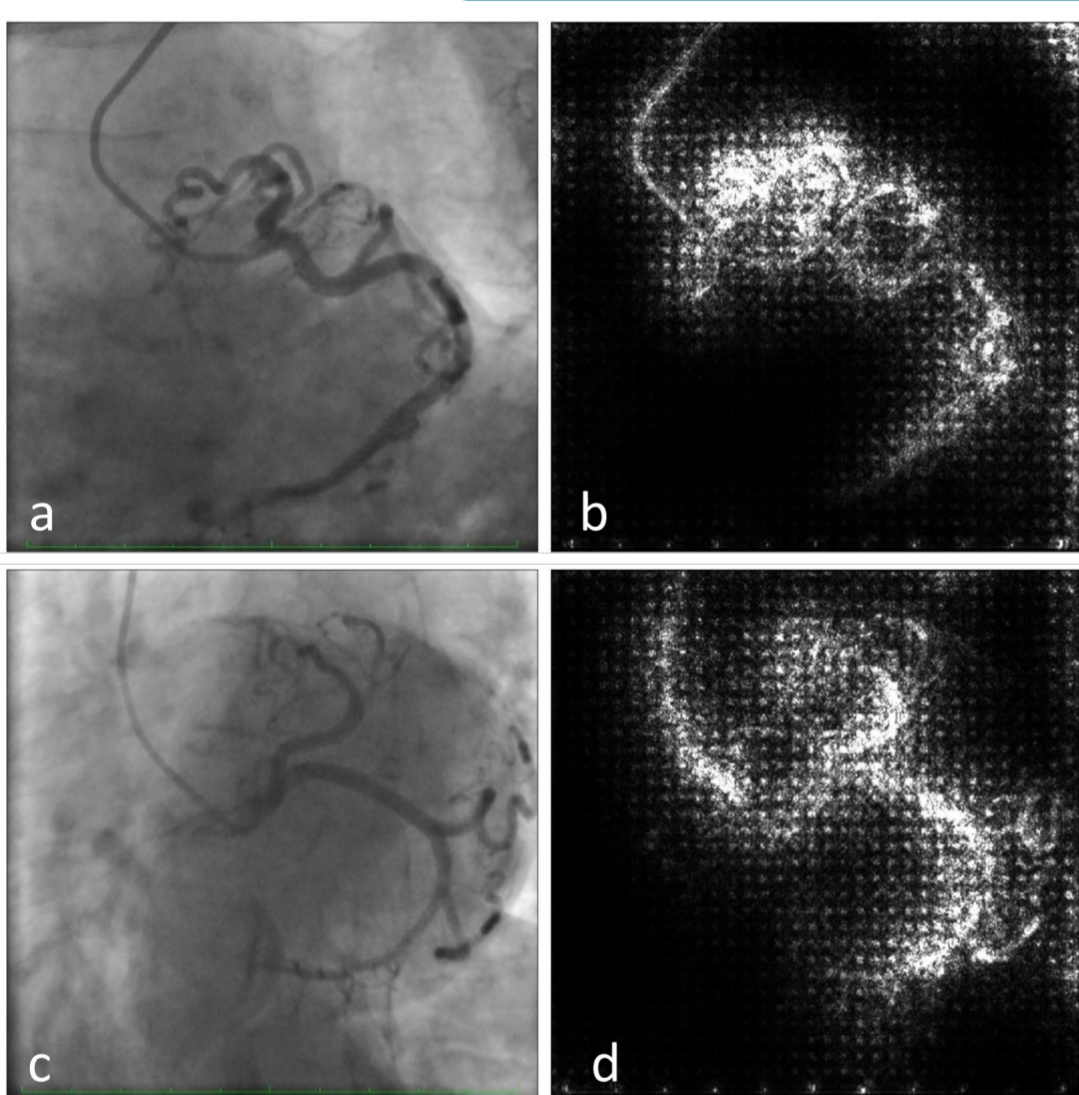


Figure 2. Saliency maps examples of left (Spider) coronary angiographies.

a-b. Patient with coronary artery tortuosity. Predicted labels: tortuous (99.8%), non-tortuous (0.2%).
c-d. Patient without coronary artery tortuosity. Predicted labels: non-tortuous (92.5%), tortuous (7.5%).

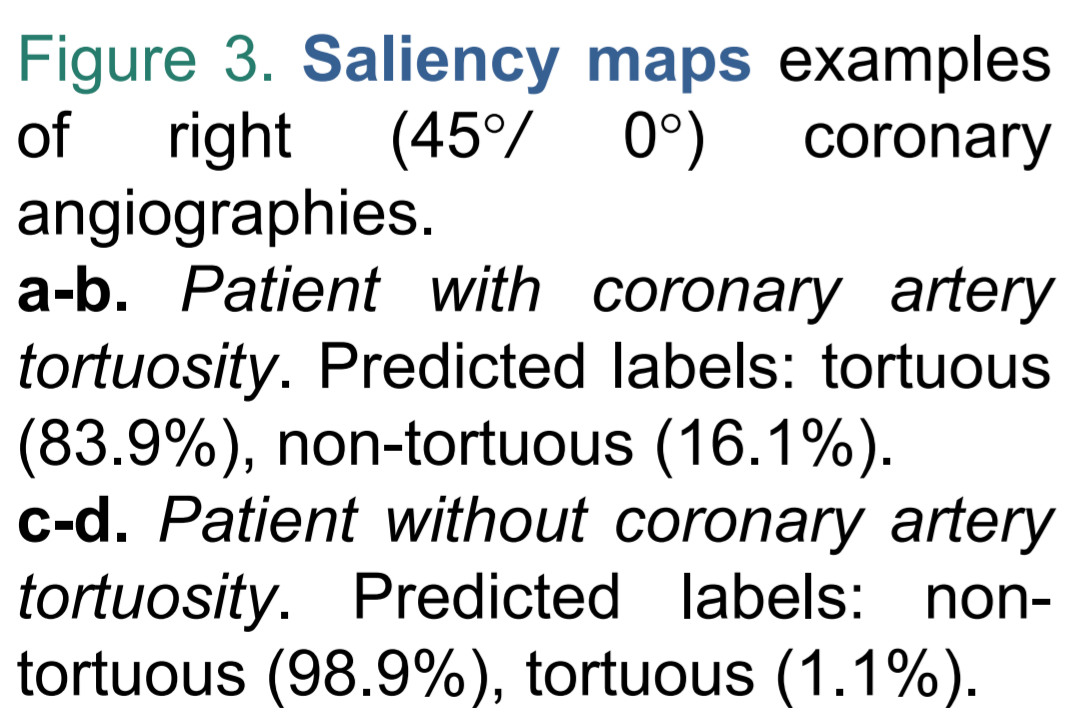


Figure 3. Saliency maps examples of right (45°/0°) coronary angiographies.

a-b. Patient with coronary artery tortuosity. Predicted labels: tortuous (83.9%), non-tortuous (16.1%).
c-d. Patient without coronary artery tortuosity. Predicted labels: non-tortuous (98.9%), tortuous (1.1%).

Metric	Mean (DL models)	SD (DL models)	Mean (RVE)	SD (RVE)
Accuracy	0.87	0.06	0.85	0.03
Sensitivity	0.87	0.10	0.84	0.02
Specificity	0.88	0.10	0.86	0.04
PPV	0.89	0.08	0.87	0.05
NPV	0.88	0.09	0.84	0.02
F ₁	0.87	0.07	0.85	0.03
AUC	0.96	0.03		

Table 1. Classification metrics for detecting CAT in CAG with DL and RVE.

- The DL algorithm, comprised of 5-fold cross-validation models, has sensitivity and specificity compatible with expert RVE for detecting CAT for a conservative threshold of 0.5.
- Expert cardiologists observe the entire radiographic sequence for visual detection of CAT versus our DL algorithm that performs automated CAT detection from a single representative image of each angiographic projection at the point of maximum arterial filling with contrast material.
- Selecting the image with the highest contrast is a minor problem, which can be solved with Artificial Intelligence methods or with classical image analysis techniques.
- Future work: increase number of images to evaluate CAG images misclassified by the DL algorithm for further validation.

CONCLUSIONS

- The DL algorithm can screen to provide the likelihood of a patient being diagnosed with CAT by adapting its threshold.
- Beneficial impact on preventing cardiac lesions, shortening CAG examination times, establishing vascular risks and improving future treatment strategies.

REFERENCES

- N. Gaibazzi, et al., "Severe coronary tortuosity or myocardial bridging in patients with chest pain, normal coronary arteries, and reversible myocardial perfusion defects," American journal of cardiology, vol. 108, no. 7, pp. 973–978, 2011.
- M. Königstein, et al., "Impact of coronary artery tortuosity on outcomes following stenting: a pooled analysis from 6 trials," JACC Cardiovascular Interventions, vol. 14, no. 9, pp. 1009–1018, 2021.
- J. Chiha, et al., "Gender differences in the prevalence of coronary artery tortuosity and its association with coronary artery disease," IJC Heart & Vasculature, vol. 14, pp. 23–27, 2017.